









## ORIGINAL RESEARCH

## Clinical and mycological investigations of post-COVID-19 acute invasive fungal sinusitis

Samah Mahmoud Eldsouky<sup>1</sup>  | Amany K. Shahat<sup>2</sup>  |  
AL-Shaimaa M. AL-Tabbakh<sup>2</sup>  | Shaymaa M. Abd El Rahman<sup>3</sup> |  
Yasmin M. Marei<sup>3</sup>  | Lina Abdelhady Mohammed<sup>3</sup>  | Ola Samir El-Shimi<sup>4</sup>  |  
Dina Saad Abdelmotaleb<sup>4</sup>  | Yomna Mohammed Marei<sup>5</sup>  |  
Mohamed Sabry Abd Elraheem Elsayed<sup>6</sup>

<sup>1</sup>Department of Otolaryngology and Head and Neck Surgery, Faculty of Medicine, Benha University, Benha City, Egypt

<sup>2</sup>Department of Medical Microbiology and Immunology, Benha University, Benha City, Egypt

<sup>3</sup>Department of Medical Biochemistry and Molecular Biology, Faculty of Medicine, Benha University, Benha City, Egypt

<sup>4</sup>Department of Clinical and Chemical Pathology, Faculty of Medicine, Benha University, Benha City, Egypt

<sup>5</sup>Department of Internal Medicine, Faculty of Medicine, Benha University, Benha City, Egypt

<sup>6</sup>Department of Bacteriology, Mycology, and Immunology, Faculty of Veterinary Medicine, University of Sadat City, Sadat City, Minufiyaa, Egypt

## Correspondence

Samah Mahmoud Eldsouky, Department of Otolaryngology and Head and Neck Surgery, Faculty of Medicine, Benha University, Benha City, Qalyubia 13511, Egypt.

Email: [samahmahmoed83@yahoo.com](mailto:samahmahmoed83@yahoo.com)

## Abstract

**Objectives:** An increased incidence of acute invasive fungal sinusitis associated with the recent COVID-19 pandemic has been observed, which is considered a public health concern. This study aims to detect the incidence, risk factors, causative agents, clinical presentations, outcomes, and susceptibility rate of various antifungals.

**Methods:** In this cross-sectional cohort study, a total of 30 patients showing acute invasive fungal rhinosinusitis following a COVID-19 infection were investigated. Histopathological biopsies, culture identification, and molecular confirmation of the causative agents were conducted. The demographic data, risk factors, clinical presentations, treatment regimen and its outcomes, and efficacy of antifungals were listed and analyzed.

**Results:** A total of 30 cases with a mean age of  $59.6 \pm 11.9$  years were included. Diabetes mellitus was the most recorded comorbidity with a rate of 86.7%, whereas most of the patients received corticosteroids. The mycological examination confirmed the existence of *Mucor* (*Rhizopus oryzae*) and *Aspergillus* (*Aspergillus niger*) in 96.7% and 3.3% of the cases, respectively. Various stages of sinonasal involvement (ethmoid, maxillary, sphenoid, and inferior turbinate) represented 100%, 83.3%, 66.7%, and 86.7% of the cases, respectively. Headache and facial pain, ophthalmoplegia, visual loss, and blindness represented 100%, 66.7%, 90%, and 53.3% of the cases, respectively. All the cases were simultaneously treated with surgical debridement and amphotericin B. Moreover, *R. oryzae* was susceptible to it, whereas *A. niger* was sensitive to voriconazole, resulting in a survival rate of 86.7% (26/30). The *R. oryzae* and *A. niger* isolates were proven to be sensitive to acetic acid, ethyl alcohol, formalin, and isopropyl alcohol.

**Conclusions:** In patients with COVID-19, the diagnosis of acute invasive fungal sinusitis and prompt treatment with antifungal medicine and surgical debridement are important in achieving better outcomes and survival rates.

**Level of Evidence:** 4

This is an open access article under the terms of the [Creative Commons Attribution-NonCommercial-NoDerivs](https://creativecommons.org/licenses/by-nc-nd/4.0/) License, which permits use and distribution in any medium, provided the original work is properly cited, the use is non-commercial and no modifications or adaptations are made.

© 2022 The Authors. *Laryngoscope Investigative Otolaryngology* published by Wiley Periodicals LLC on behalf of The Triological Society.

## KEYWORDS

antifungals, COVID-19, mucormycosis, polymerase chain reaction, sinusitis

## 1 | INTRODUCTION

The development of severe acute respiratory syndrome coronavirus 2 in China at the end of 2019 has resulted in a significant global outbreak and has been considered a serious public health concern.<sup>1</sup> Some fungal illnesses have symptoms that are similar to those of COVID-19, such as fever, cough, and shortness of breath.<sup>2</sup> To identify if a person has a fungal infection or COVID-19, laboratory testing is required. COVID-19 and fungal infections might occur in the same patient. People who have severe COVID-19, such as those who are in the intensive care unit (ICU), are especially susceptible to bacterial and fungal infections. Mucormycosis is an angioinvasive fungal illness caused by saprophytic aerobic fungus and spreads through the inhalation of spores in the environment. The spores subsequently colonize the nasal or sinus mucosa, wherein phagocytes destroy the spores of the inhaled fungi in immunocompetent individuals, but in those with reduced immunity, the spores may act as opportunistic infections. Germination and the development of hyphae are aided in individuals with diabetes by elevated blood sugar levels, which are followed by vascular invasion and local tissue proliferation.<sup>3</sup> Although COVID-19-associated mucormycosis is less prevalent than the other COVID-19-associated fungal infections, new studies from India emphasize the necessity of taking this infection into account. Some drugs used to treat severe COVID-19, such as high-dose corticosteroids and tocilizumab, may increase the risk of mucormycosis in patients with COVID-19.<sup>4</sup> According to scientists, aspergillosis was assumed to affect virtually only patients with very impaired immune systems. However, aspergillosis is becoming more common in people who do not have a compromised immune system but have severe viral respiratory infections, such as influenza. COVID-19-related pulmonary aspergillosis has been reported in several recent studies.<sup>2,5,6</sup> Antifungal medications treat fungal infections by destroying or preventing hazardous fungi from growing in the body. Antimicrobial resistance can occur in fungus, just as it can in bacteria. This resistance can develop when antifungal medications are administered incorrectly to treat sick people (e.g., when dosages are too low or treatment periods are too short) or even when antifungal drugs are used correctly.<sup>7,8</sup> Fungicides are used in agriculture to prevent and treat fungal diseases in crops, but they can also cause resistance in individuals who are exposed to them. Controlling mucormycosis requires sterilization and disinfection of equipment used by several patients (tracheal tubes and ventilators), as well as ventilation systems.<sup>9</sup> Moreover, the disinfection of hospitals, patient clinics, laboratories, and all the devices utilized for patients is essential for controlling fungal infections. Microbial typing utilizing DNA-based molecular approaches was found to be quick and accurate, particularly for rRNA genes, which are extensively utilized for fungal phylogenetic detection.<sup>10-12</sup> Because mucormycosis is a rare infection, genetic research on this disease is limited. To identify the therapeutically significant zygomycetes, the researchers employed the 28S rRNA gene<sup>13</sup> as well as the actin and elongation factor-1 alpha genes.<sup>14</sup> However, no

polymerase chain reaction (PCR) differentiation of all potential human pathogenic *Rhizopus* species has been performed, and distinction using the highly variable internal transcribed spacer (ITS) region would be acceptable.

The aims of this study are to clinically investigate invasive fungal sinusitis and make the mycological identification of causative fungal agents with the implementation of molecular techniques for the confirmation of these agents. Moreover, the susceptibility of the identified fungal agents to various antifungals will be determined.

## 2 | METHODS

### 2.1 | Participants

A total number of 30 patients (Table 1), who were diagnosed with acute invasive fungal rhinosinusitis (AIFR) associated with recent COVID-19 infection and treated at Benha University's Department of Otorhinolaryngology from July to December 2020 were included in this study. All of the patients received a clear diagnosis of COVID-19 based on the results of the PCR test and computed tomography (CT) scan. According to the most recent recommendations, invasive fungal sinusitis was diagnosed.<sup>15,16</sup> It includes a short-term (<4 weeks) course with histopathological evidence of fungal invasion in the sinus mucosa, submucosa, or bone. The nearly estimated 2 weeks period was not for waiting, it was the elapsed time between the negative COVID test result and the appearance of AIFR signs. The patients were diagnosed on the same day and received the recommended treatment. The patients with missing or partial data were excluded from the study. Patient demographics, presenting signs and symptoms, imaging results, pathology data, medical and surgical treatment modalities, and clinical outcomes were collected and evaluated after the institutional review board's permission and signed consent from the study population were obtained.

### 2.2 | Investigations

For all the patients, CT scans of the chest, nose, and paranasal sinuses were obtained. When ocular or cerebral involvement was suspected, magnetic resonance imaging investigations were conducted. Sinus thrombosis was also assessed using magnetic resonance venography. The patients were biopsied for histopathological and microbiological confirmation of AIFR and detection of the causative organism. The histopathological diagnosis was determined from the morphology via the Grocott Methenamine Silver-Nitrate staining. The differentiation between the *Mucor* and *Aspergillus* species is based on their cultural characteristics and microscopic appearance after staining fungal slides with Lactophenol Cotton Blue stain.

**TABLE 1** Data of cases, the existence of comorbidities, causative fungal agents, medical and surgical management, and the outcomes of the acute invasive fungal sinusitis in post-COVID-19 patients

Aspects of difference	Number	Frequency (%)
Patients	30	100
Age (years) (mean ± SD)	59.6 ± 11.9	
Sex (male/female)	20/10	66.7/33.3
Comorbidities		
Cardiac	5	16.7
Chest	4	13.3
Diabetes mellitus (DM)	26	86.7
Hypertension (HNT)	20	66.7
Malignancy	1	3.33
Elapsed days since COVID-19 diagnosis (mean ± SD)	16.7 ± 1.97	
Fungal agent		
<i>Mucor (Rhizopus oryzae)</i>	29	96.7
<i>Aspergillus (Aspergillus niger)</i>	1	3.3
Therapy with amphotericin B		
Susceptible	29	96.7
Resistant	1	3.3
Survive	26	86.7
Dead	4	13.3
Clinical extension		
Nasal		
Ethmoid	30	100
Frontal	8	26.7
Maxillary	25	83.3
Sphenoid	20	66.7
Septum	25	83.3
Lateral nasal wall	9	30
Lacrimal duct	4	13.3
Turbinate	26	86.7
Orbit		
Subperiosteal abscess	2	6.7
Orbital extension	20	66.7
Ophthalmoplegia	20	66.7
Intracranial		
Cavernous sinus	10	33.3
Symptoms		
Nasal		
Headache	30	100
VII pain	30	100
Nasal discharge	30	100
Orbit		
Ophthalmoplegia	25	83.3
Proptosis	10	33.3
Visual loss	27	90

(Continues)

**TABLE 1** (Continued)

Aspects of difference	Number	Frequency (%)
Diplopia	9	30
Blindness	16	53.3
Ptosis	5	16.7
Cranial		
Altered mental state	4	13.3
VII nerve palsy	8	26.7
Bulbar palsy	2	6.7
Palatal necrosis	8	26.7
Predisposing factors		
Antibiotic	30	100
Corticosteroid	26	86.7
O <sub>2</sub> therapy	25	83.3

## 2.3 | Interventions

Antifungal drugs and surgery with the management of any underlying medical conditions were used. In this study, antifungal medication was the primary treatment for individuals with post-COVID-19 fungal infections. The antifungal medication, such as amphotericin B, was commonly used, and it was prescribed by infectious disease specialists based on the organism found and the patient's state along with therapeutic drug monitoring. Surgical intervention was not conducted unless two consecutive negative COVID-19 swab findings were obtained. The surgical approach was customized based on the findings of each patient and the extent of the infection. To remove infection, endoscopic, open, and combination methods were used, along with serial debridement. Anticoagulants were used to treat cerebral sinus thrombosis in collaboration with neurology experts. After two endoscopic negative histopathologic examinations, the patients were declared free of fungal infection. The survivors were subjected to monthly ambulatory endoscopic evaluations during the follow-up period to ensure disease eradication.

## 2.4 | Isolation and identification

The biopsies from infected cases were cultivated onto Sabouraud 4% dextrose agar plates (Difco, Detroit, I11) and incubated at 30°C for 3–4 days at the Department of Microbiology, Faculty of Medicine, Benha University.

## 2.5 | Morphological characterization

The observation of the macroscopic and microscopic characters of *Rhizopus oryzae* was confirmed as described by Schipper and Stalpers<sup>17</sup> and Vebliza et al.<sup>18</sup> In addition, *Aspergillus niger* was confirmed as described by Gautam and Bhadauria,<sup>19</sup> by septated hyphae, two series of phialides covering the entire vesicle.

## 2.6 | Molecular confirmation

### 2.6.1 | DNA extraction from fungal cultures

The DNeasy tissue kit (QIAGEN), which relies on the binding of the DNA to silica columns, was used in accordance with the manufacturer's instructions.

### 2.6.2 | PCR protocol

The PCR protocol was modified from the multiplex protocol of Nagao et al.<sup>20</sup> to a simplex protocol. Four different primers (Table 2) targeting the fragments of the ITS region of the *Rhizopus* rRNA genes were amplified using the HotstarTaq Master Mix (QIAGEN) with cycling conditions at 94°C for 15 min and 34 cycles at 94°C for 15 s, 57°C for 30 s, and 72°C for 1 min for *Rhizopus azygosporus*, *Rhizopus microsporus*, *Rhizopus stolonifer*, and *Rhizopus schipperae*, respectively, whereas for *R. oryzae* and *A. niger*, the annealing temperature was at 60°C for 30 s. The QIAxcel machine and specified software for data analysis were used for the visualization of the PCR amplification products. The *R. oryzae* HUMC 02 and *A. niger* ATCC 1015 were used as positive controls.

The specific primers were designed using the Lasergene v.8.0.2 software (DNASTAR Inc., USA) based on the ITS region and glucose dehydrogenase genes published in GenBank for *Rhizopus* rRNA and *Aspergillus* sp., respectively.

### 2.6.3 | Minimal inhibitory and fungicidal concentrations

The performed protocol used to determine the minimal inhibitory concentration (MIC) and fungicidal concentration was similar to that of Bailey<sup>21</sup> and Fuangsawat et al.<sup>22</sup> The fungi were refreshed on Petri dishes containing 15 ml of Sabouraud dextrose agar and incubated at 20°C for 3–4 days. The hyphae at the edge of each growing colony

were sampled using an L-shaped loop. The hyphae were cultivated in Sabouraud dextrose agar dishes containing 0.1%–75% acetic acid (Frankfurt, Germany), 50–250 µg/ml amphotericin B (Astellas Pharma, USA), 0.5%–1% ethyl alcohol (Sigma-Aldrich, USA), and 0.1%–0.5% formalin (Sigma-Aldrich, USA). In addition to the previously used chemicals, 1%–10% isopropyl alcohol (Sigma-Aldrich, USA), 0.5%–1% chlorine (Sigma-Aldrich, USA), 10%–40% hydrogen peroxide (Sigma-Aldrich, USA), 1%–10% iodine (Sigma-Aldrich, USA), 5%–40% sodium chloride (Sigma-Aldrich, USA), and 1–50 µg/ml voriconazole (MedChemExpress, USA) were also tested. The plates were investigated daily for the appearance of growth, and the diameter of each fungal colony was measured daily for 5 days using specified calipers (available from [www.ncss.com](http://www.ncss.com)). The MIC was determined as the minimal concentration of the chemical that produced an average diameter of the colony significantly ( $p < .05$ ) smaller than that of the control group, whereas the fungicidal concentration was determined as the concentration of the chemical agent that prevented the fungal growth for 5 days.

## 3 | RESULTS

A total of 30 patients were diagnosed with AIFR post-COVID-19 infection. The elapsed time since COVID-19 diagnosis was  $16.7 \pm 1.97$  days, with a mean age of  $59.6 \pm 11.9$  years. Table 1 shows the demographic and clinical data and comorbidities of the patients. The most noticeable comorbidities were diabetes mellitus (DM) and hypertension with incidence rates of 86.7% and 66.7%, respectively. One patient was confirmed with connected malignancy and leukemia which represented 3.33% of the cases.

The histopathological examination of mucosal biopsies confirmed the existence of *Mucor* species (96.7%) and *A. niger* (3.3%) (Table 1). Table 1 shows the brief presentation of signs and symptoms. Endoscopic findings and CT scan showed various stages of sinonasal affections: ethmoid (100%), maxillary (83.3%), sphenoid (66.7%), frontal (26.7%), septum (83.3%), inferior turbinate (86.7%), lateral nasal wall (30%), lacrimal duct (13.3%), and palatal involvement (26.7%).

**TABLE 2** Primer sequences, annealing temperature, and amplicon sizes

Species	Primers	Annealing temperature (°C)	Size of PCR product (bp)	References
<i>Rhizopus oryzae</i>	F: 5'-CTTTGAACGCAGCTTGCAC-3' R: 5'-AGTTCAGCGGGTAATCCCAC-3'	60	552	This study
<i>Rhizopus azygosporus</i> <i>Rhizopus microsporus</i>	F: 5'-GCACTTTACTGGGATTTACTTCTCA-3' R: 5'-CACGATGGCTAGGTAGTTCGTAAT-3'	57	525	[20]
<i>Rhizopus stolonifer</i>	F: 5'-CAACCCATCATCTCTTTACTGTGAA-3' R: 5'-CTCTCCCTTCTGCATAATCGTTA-3'	57	663	
<i>Rhizopus schipperae</i>	F: 5'-GGTGATCAAGGATTGTAATGATCTTTGT-3' R: 5'-CATCCATAACCACATAGAGTATATGTGT-3'	57	272	
<i>Aspergillus niger</i>	F: 5'-ATCTCTTGGTCCGGCATCG-3' R: 5'-AATGGTTGAAAACGTCGGC-3'	60	301	This study

Abbreviation: PCR, polymerase chain reaction.

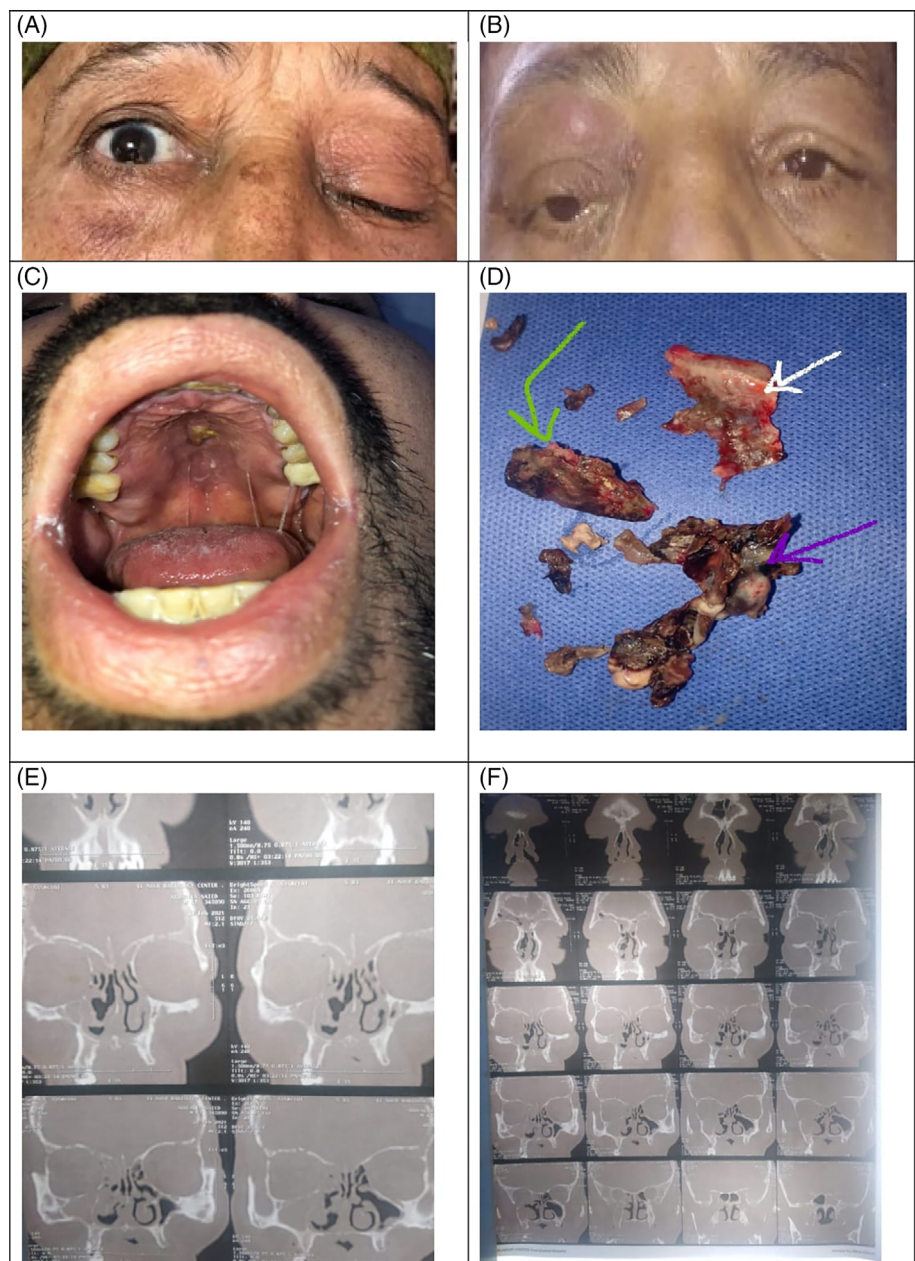


Headache and facial pain (100%) and ophthalmoplegia (66.7%) were the most common signs and symptoms (Figure 1A,B,D). Proptosis was documented in 10 patients, and 9 patients complained of diplopia. Palatal affection had variable patterns that involved palatal ulcers with necrosis (Figure 1C,D).

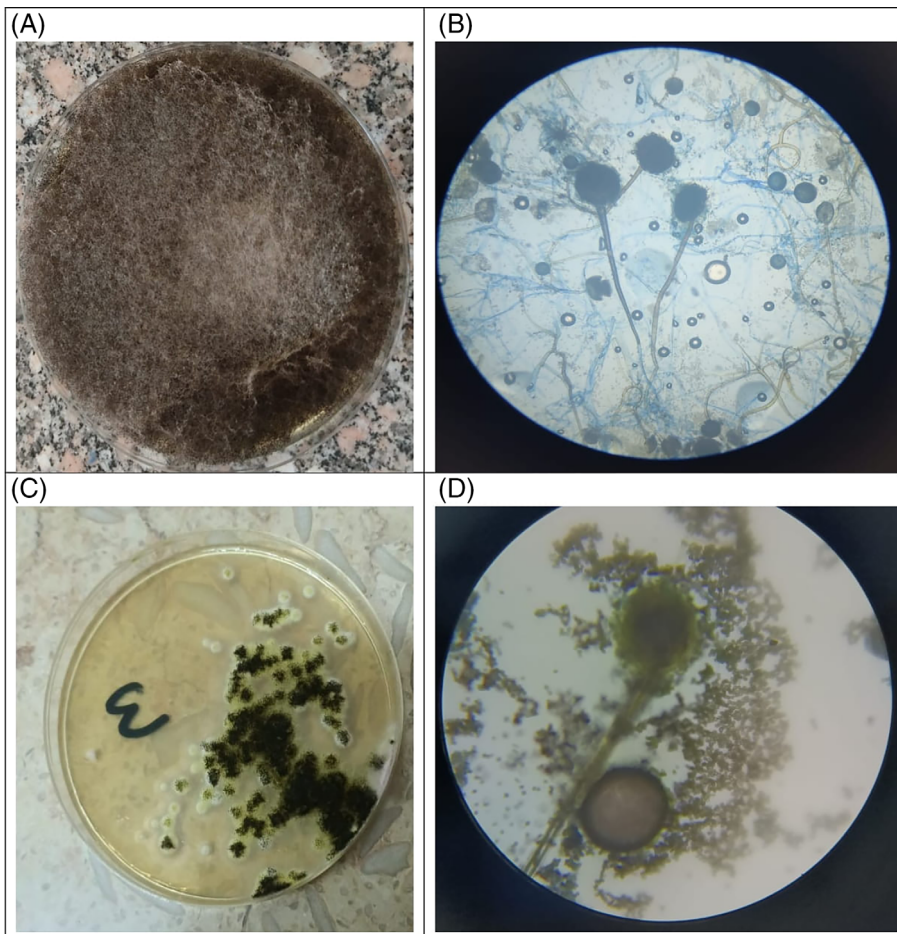
The CT scans of the chest revealed highly positive findings of COVID-19 in 100% of the patients. The radiological studies on the nose and paranasal sinuses showed variable patterns (Figure 1E,F). Those patterns range from the mucosal thickening of the involved sinus mucosa to osteomyelitis of the related bone. Orbital involvement showed evidence of either subperiosteal abscess in two cases with a rate of 6.7% (Figure 1B) and 5.6%. All 10 patients with intracranial extension had cavernous sinus thrombosis.

The treatment protocol for hospitalized patients consisted of antivirals, anticoagulants, vitamins, and steroids. Steroid treatment was

reserved for some selected moderate (1 mg/kg/day) and severe (1–2 mg/kg/day) cases. The classification and treatment of the patients have been implemented according to the national management protocol guidelines provided by the Ministry of Health and Population in Egypt. In the treatment of AIFR, all the patients in the present study had undergone combined antifungal therapy and surgery. Liposomal amphotericin B was administered to 29 patients and voriconazole to 1 patient. The surgical approach was purely endoscopic in 28 (93.3%) patients, whereas combined endoscopic and open approaches were utilized in the remaining 2 patients. Endoscopic debridement included the resection of the middle turbinate, wide middle meatal antrostomy, ethmoidectomy, sphenoidotomy, and Draf III in some cases according to the involved sinuses. Orbital involvement in this case series was managed using a wide variety of surgical approaches including the endoscopic evacuation of



**FIGURE 1** Palatal involvement, inflammatory changes in nasal wall and eye, radiological findings of paranasal sinus fungal sinusitis. (A) Female with right facial palsy. (B) Male with right orbital complication. (C) Male with a palatal ulcer. (D) Surgical debridement, the white arrow from the septum, the green arrow from the lamina papyracea, and the purple arrow from the middle turbinate. (E) and (F) Radiological showing computed tomography of paranasal sinus fungal sinusitis



**FIGURE 2** Macroscopic and microscopic characters of the detected fungal agents. (A) and (B) *Rhizopus oryzae*. (C) and (D) *Aspergillus niger*

subperiosteal abscess, orbitotomy, orbital decompression, and orbital exenteration in the case of orbital invasion with blindness. Palatal necrosis was managed either via infrastructure maxillectomy or palatotomy according to the extension of necrosis with post debridement obturator insertion (Figure 1D). The overall survival was 86.7% (26/30) at the conclusion of the study, and 4 patients (13.3%) died.

### 3.1 | Isolation and identification

A total of 30/30 (100%) fungal isolates were gained, whereas 29/30 (96.7%) isolates were identified as *R. oryzae*, which was characterized by grayish brown colonies and brownish rhizoids and sporangio-phores. The sporangiophores have more than two branches, whereas the sporangia are grayish black and powdery. The zygospores are reddish brown in young culture but are brown in old culture. Furthermore, 1/30 (3.3%) was identified *A. niger*, which was characterized by rapid growth, dark brown to black culture surface, entire margins, umbonated elevations, branched septated hyphae, two series of phialides covering the entire vesicle (Table 1 and Figure 2). A significant difference between the isolation rates of both fungal agents was observed ( $p < .05$ ).



**FIGURE 3** Electrophoresis of the polymerase chain reaction products using the QIAxcel machine. Lane 3 is a control-positive *Rhizopus oryzae* HUMC 02 with a band size of 552 bp, while Lane 2 is a control-positive *Aspergillus niger* ATCC 1015 with a band size of 301 bp. Lane 3 is a control-negative *Escherichia coli* isolate. Lanes 4–11 are positive isolates for *R. oryzae*. Lane 12 is an appositive isolate for *A. niger*

**TABLE 3** Efficacy of some antifungals

No.	Antifungal	<i>Rhizopus oryzae</i>		<i>Aspergillus niger</i>		Minimum inhibitory concentration	Minimum fungicidal concentration
		Sensitive	Resistant	Sensitive	Resistant		
1	Acetic acid	Positive	Negative	Positive	Negative	0.5%	0.75%
2	Amphotericin B	Positive	Negative	Negative	Positive	200 µg/ml	250 µg/ml
3	Ethyl alcohol	Positive	Negative	Positive	Negative	0.75 ml of 70%	1 ml of 70%
4	Formalin	Positive	Negative	Positive	Negative	0.2%	1 ml of 0.5%
5	Isopropyl alcohol	Positive	Negative	Positive	Negative	0.75 ml of 70%	1 ml of 70%
6	Chlorine	Negative	positive	Negative	Positive	Ineffective	Ineffective
7	Hydrogen peroxide	Negative	Positive	Negative	Positive	Ineffective	Ineffective
8	Iodine	Negative	Positive	Negative	Positive	Ineffective	Ineffective
9	Sodium chloride	Negative	Positive	Negative	Positive	Ineffective	Ineffective
10	Voriconazole	Negative	Negative	Positive	Negative	3 µg/ml <sup>a</sup>	4 µg/ml <sup>a</sup>

<sup>a</sup>The minimal inhibitory concentration and minimum fungicidal concentration of Voriconazole on *Aspergillus niger*.

### 3.2 | Molecular confirmation

The implementation of the PCR using specific primers targeting the fragments of the ITS region of *Rhizopus* rRNA genes confirmed that 29/30 (96.7%) of the fungal isolates were *R. oryzae*, whereas 1/30 (3.3%) was *A. niger* (Figure 3). A strong association was observed between the results of the PCR test and those of the isolation and microscopical examination.

### 3.3 | Efficacy of antifungals

All of the *R. oryzae* and *A. niger* isolates showed sensitivity to acetic acid, ethyl alcohol, formalin, and isopropyl alcohol with a MIC of 0.5%, 0.75 ml of 70%, 0.2%, and 0.75 ml of 70%, respectively. Conversely, the minimum fungicidal concentrations for these products were 0.75%, 1 ml of 70%, 0.5%, and 1 ml of 70%, respectively. Furthermore, only the *R. oryzae* isolates were sensitive to amphotericin B with an MIC of 200 µg/ml and a minimum fungicidal concentration of 250 µg/ml. Both *R. oryzae* and *A. niger* were resistant to chlorine, hydrogen peroxide, iodine, and sodium chloride. Moreover, the resistant *A. niger* isolate was sensitive to voriconazole and the MIC and minimum fungicidal concentration were 3 µg/ml and 4 µg/ml, respectively, while *R. oryzae* isolates were resistant to it (Table 3).

## 4 | DISCUSSION

Several therapeutic agents were examined to determine their efficacy since the emergence of COVID-19 (e.g., antivirals, corticosteroids, and immunomodulatory agents), and none were proven to be clinically efficacious.<sup>23,24</sup> Systemic corticosteroids have been proven to reduce mortality in specific subgroups of patients with COVID-19, with the greatest efficacy observed in individuals who require invasive mechanical breathing. Nonetheless, systemic corticosteroids depress the immune system, predisposing patients to invasive fungal

rhinosinusitis.<sup>25,26</sup> DM with or without diabetic ketoacidosis, malignancies, being a transplant recipient, chronic neutropenia, and immunosuppressive and corticosteroid therapy are all common risk factors in non-COVID-19 patients with mucormycosis.<sup>27,28</sup> This results in a high rate of deadly fungal infection affecting the nose and paranasal sinuses, with the rhino-orbito-cerebral presentation being the most prevalent.<sup>25-28</sup> The COVID-19-associated AIFR differs from that of the non-COVID-19 in both existences of some remarkable risk factors and high incidence rate. The upregulation of inflammatory cytokines and reduced cell-mediated immunity with decreasing levels of CD4<sup>+</sup> and CD8<sup>+</sup> cells might both be related to COVID-19. Further contributing variables to the COVID-19-linked AIFR include steroid-induced hyperglycemia, diabetic ketoacidosis, elevated iron levels, immunosuppression (from COVID-19, excessive steroid dosages, and immunomodulators, and reduced white blood cells phagocytic activity. Additionally, extended hospitalization with or without mechanical ventilators and low oxygen levels both increase the risk of AIFR.<sup>29-31</sup> Compared to non-COVID-19 individuals, the incidence of AIFR is noticeably higher in immunocompromised, diabetic, renal, and hepatic dysfunction patients, as well as those with cardiac illnesses, bronchial asthma, and obesity.<sup>32</sup> The incidence of fungal infections was within a rate of 0.005–1.7 persons per one million population, which was lower than that in India, which reached 80 times higher than the registered records.<sup>30</sup> Print and electronic media have reported multiple cases of major public health implications, especially because mucormycosis has a high mortality rate. Mucormycosis intracranial involvement, in particular, increases the mortality rate to 90%. Furthermore, the velocity with which mucormycosis spreads is an exceptional phenomenon, and even a 12-h delay in diagnosis can be lethal, which is why 50% of patients with mucormycosis have traditionally been diagnosed only in postmortem autopsies series.<sup>33,34</sup> The current cross-sectional cohort analysis comprised 30 patients with acute invasive fungal sinusitis who had a previous COVID-19 diagnosis at a tertiary-level university hospital. Regarding the demographics of the cases, their ages ranged from 42 to 73 years (mean: 59.6 ± 11.9 years), and the male-to-female ratio was 20:10. Concerning the gender



distribution, our results indicated the prevalence of male patients, coinciding with the results of Sharma et al.,<sup>35</sup> who reported the prevalence of men among 23 patients: 15 were men and 8 were women. In the present study, most of the cases have acquired fungal infection after their recovery from COVID-19, which is consistent with the findings of Sharma et al.<sup>35</sup> and Benhadid-Brahmi et al.,<sup>36</sup> who reported that mucormycosis developed after recovery from COVID-19, as well as during the active course of the disease. Moreover, aspergillosis has been associated with COVID-19. In the present study, the cases presented with unilateral sinonasal disease affecting the ethmoid (100%) and (83.3%) maxillary sinuses. Cavernous sinus thrombosis was observed in 10 patients (33.3%), facial nerve palsy in 8 patients (26.7%), and palatal involvement in 8 patients (26.7%). These findings are consistent with those of Sharma et al.<sup>35</sup> Concerning the orbital signs, which were unilateral in all patients, proptosis was the most frequent (10 patients; 33.3%). Ophthalmoplegia was found in 25 patients (83.3%). Singh et al.<sup>30</sup> reported an orbital involvement rate of 56.7%. Moreover, El-Kholy et al.<sup>16</sup> found that the rates of ophthalmoplegia and proptosis were 63.9% and 52.8%, respectively. The increased rates of orbital and intracranial extension could be attributed to the delayed presentation. In the present study, it can be concluded that the outcome was time critical. A number of four patients (13.3%) did not receive surgical therapy because they died during the first 48 h of ICU admission because of the delayed presentation. The discrimination of the fungal agents that cause serious problems was based on cultural and microscopic characteristics. However, some fungi are genetically quite similar and morphologically indistinguishable. Hence, DNA-based molecular investigation of clinically significant zygomycetes has proven to be quick and accurate, particularly for rRNA genes, and has become widely accepted for phylogenetic identification.<sup>20</sup> The present study used morphological, microscopic, and molecular-based methods for the identification of the fungal agents causing post-COVID-19 invasive fungal sinusitis. The susceptibility of *R. oryzae* and *A. niger* to acetic acid, ethyl alcohol, formalin, and isopropyl alcohol was also confirmed. In the present study, the efficacy of acetic acid on *R. oryzae* was similar to that in the study of Ghasemian et al.<sup>37</sup> Moreover, the efficacy of ethanol on *R. oryzae* was nearly similar to Uyar and Uyar,<sup>38</sup> who confirmed the lethality of ethanol on the *R. oryzae* spores. Although the efficacy of formalin and isopropyl alcohol on *R. oryzae* has not yet been investigated, this study is the first to confirm the susceptibility of *R. oryzae* to both disinfectants. The efficacy of the tested disinfectants on *A. niger* was nearly similar to Korukluoglu et al.,<sup>39</sup> except for formalin as they proved that aldehydes are ineffective against *A. niger*. The susceptibility of all the *R. oryzae* isolates to amphotericin B in the present study is consistent with the findings of Cornely et al.<sup>40</sup> who stated that for the individuals who can tolerate the nephrotoxic side effects, amphotericin B is the current first-line treatment for invasive mucormycosis. Although we gained one isolate of *A. niger*, it expressed resistance to amphotericin B. This is contrary to the findings of Romero et al.<sup>41</sup> who proved that seven isolates of *A. niger* were susceptible to this antifungal. The *A. niger* isolate was sensitive to voriconazole which was not effective against *R. oryzae* isolates which come in

agreement with Arikan et al.<sup>42</sup> The rational interpretation of amphotericin B and voriconazole resistance in *A. niger* and *R. oryzae*, respectively could be attributed to decreased absorption, increased activities of efflux pumps, and/or enhanced activity of catalase to lower the oxidative stress caused by the utilized antifungal.<sup>43,44</sup> The existence of resistance could be geographically specific, and it could lead to treatment failure, extended period of hospitalization, and life-threatening conditions.

The limitations of this study include a small patient population, the absence of topic experience center, and a short follow-up period. Furthermore, no alternatives to amphotericin B are available. Future studies are needed to update the required experience with a long-term follow-up period and to compare a broader group of patients along with the assessment of risk factors associated with COVID-19 and acute invasive fungal sinusitis infections.

## 5 | CONCLUSIONS

The incidence of acute invasive fungal sinusitis is increasing during the COVID-19 pandemic, making it a public health threat. The increased incidence rate of DM and the intensive administration of corticosteroids are considered major predisposing factors for such problem. Early and effective diagnosis is essential to avoid harmful complications, such as infections. Continuous monitoring of effective antifungals and disinfectants are essential factors for controlling this notorious disease and to determine the levels of resistance to antifungals.

## FUNDING INFORMATION

The authors declare no financial support or interest in this study.

## CONFLICT OF INTEREST

The authors declare no conflict of interest.

## ORCID

Samah Mahmoud Eldsouky  <https://orcid.org/0000-0002-0746-6108>

Amany K. Shahat  <https://orcid.org/0000-0001-5303-726X>

AL-Shaimaa M. AL-Tabbakh  <https://orcid.org/0000-0001-6637-0387>

Yasmin M. Marei  <https://orcid.org/0000-0002-8370-6812>

Lina Abdelhady Mohammed  <https://orcid.org/0000-0002-6332-2977>

Ola Samir El-Shimi  <https://orcid.org/0000-0001-8276-8352>

Dina Saad Abdelmotaleb  <https://orcid.org/0000-0002-9345-2553>

Yomna Mohammed Marei  <https://orcid.org/0000-0002-0932-2626>

## REFERENCES

- Lai CC, Shih TP, Ko WC, Tang HJ, Hsueh PR. Severe acute respiratory syndrome coronavirus 2 (SARS-CoV-2) and coronavirus disease-2019 (COVID-19): the epidemic and the challenges. *Int J Antimicrob Agents*. 2020;55(3):105924. doi:10.1016/j.ijantimicag.2020.105924

2. Hoenigl M. Invasive fungal disease complicating COVID-19: when it rains it pours external icon. *Clin Infect Dis*. 2021;73(7):e1645-e1648. doi:10.1093/cid/ciaa1342
3. Rammaert B, Lanternier F, Poirée S, Kania R, Lortholary O. Diabetes and mucormycosis: a complex interplay. *Diabetes Metab*. 2012;38(3):193-204. doi:10.1016/j.diabet.2012.01.002
4. Rabagliati R, Rodríguez N, Núñez C, Huete A, Bravo S, García P. COVID-19-associated mold infection in critically ill patients, Chile. *Emerg Infect Dis*. 2021;27(5):1454-1456. doi:10.3201/eid2705.204412
5. Lansbury L, Lim B, Baskaran V, Lim WS. Co-infections in people with COVID-19: a systematic review and meta-analysis. *J Infect*. 2020;81(2):266-275. doi:10.1016/j.jinf.2020.05.046
6. Koehler P, Cornely OA, Böttiger BW, et al. COVID-19 associated pulmonary aspergillosis. *Mycoses*. 2020;63(6):528-534. doi:10.1111/myc.13096
7. Lortholary O, Desnos-Ollivier M, Sitbon K, et al. Recent exposure to caspofungin or fluconazole influences the epidemiology of candidemia: a prospective multicenter study involving 2,441 patients. *Antimicrob Agents Chemother*. 2011;55(2):532-538. doi:10.1128/AAC.01128-10
8. Shah DN, Yau R, Lasco TM, et al. Impact of prior inappropriate fluconazole dosing on isolation of fluconazole-nonsusceptible *Candida* species in hospitalized patients with candidemia. *Antimicrob Agents Chemother*. 2012;56(6):3239-3243. doi:10.1128/AAC.00019-12
9. Guideline for management of Mucormycosis in Covid – 19 patients. DGHS. Accessed on May 26, 2021 from <https://dghs.gov.in/WriteReadData/News/202105171119301555988MucormycosismanagementinCovid-19.pdf>
10. Kurtzman CP, Robnett CJ. Identification and phylogeny of ascomycetous yeasts from analysis of nuclear large subunit (26 S) ribosomal DNA partial sequences. *Antonie Van Leeuwenhoek*. 1998;73(4):331-371. doi:10.1023/a:1001761008817
11. Makimura K, Tamura Y, Mochizuki T, et al. Phylogenetic classification and species identification of dermatophyte strains based on DNA sequences of nuclear ribosomal internal transcribed spacer 1 regions. *J Clin Microbiol*. 1999;37(4):920-924. doi:10.1128/JCM.37.4.920-924.1999
12. Jackson CJ, Barton RC, Evans EG. Species identification and strain differentiation of dermatophyte fungi by analysis of ribosomal-DNA intergenic spacer regions. *J Clin Microbiol*. 1999;37(4):931-936. doi:10.1128/JCM.37.4.931-936.1999
13. Voigt K, Cigelnik E, O'donnell K. Phylogeny and PCR identification of clinically important Zygomycetes based on nuclear ribosomal-DNA sequence data. *J Clin Microbiol*. 1999;37(12):3957-3964. doi:10.1128/JCM.37.12.3957-3964.1999
14. Voigt K, Wöstemeyer J. Phylogeny and origin of 82 zygomycetes from all 54 genera of the Mucorales and Mortierellales based on combined analysis of Actin and translation elongation factor EF-1alpha genes. *Gene*. 2001;270(1-2):113-120. doi:10.1016/s0378-1119(01)00464-4
15. Chakrabarti A, Denning DW, Ferguson BJ, et al. Fungal rhinosinusitis: a categorization and definitional schema addressing current controversies. *Laryngoscope*. 2009;119(9):1809-1818. doi:10.1002/lary.20520
16. El-Kholy NA, El-Fattah AMA, Khafagy YW. Invasive fungal sinusitis in post COVID-19 patients: a new clinical entity. *Laryngoscope*. 2021;131(12):2652-2658. doi:10.1002/lary.29632
17. Schipper MAA, Stalpers JA. A revision of the genus *Rhizopus*. *Studies Mycol*. 1984;25:34.
18. Vebliza Y, Sjamsurizdal W, Oetari A, et al. Re-identification of five strains of *Rhizopus arrhizus* from tempeh based on ITS regions of rDNA sequence data. *AIP Conf Proc*. 2018;2023:020167. doi:10.1063/1.5064164
19. Gautam A K, Bhadauria R. Characterization of *Aspergillus* species associated with commercially stored triphala powder. *Afr J Biotechnol* 2012; 11(104): 16814–16823. Available online at <http://www.academicjournals.org/AJB>.
20. Nagao K, Ota T, Tanikawa A, et al. Genetic identification and detection of human pathogenic *Rhizopus* species, a major mucormycosis agent, by multiplex PCR based on internal transcribed spacer region of rRNA gene. *J Dermatol Sci*. 2005;39(1):23-31. doi:10.1016/j.jdermsci.2005.01.010
21. Bailey TA. Method for in vitro screening of aquatic fungicides. *J Fish Dis*. 1983;6:91-100.
22. Fuangsawat W, Abking N, Lawhavinit O. Sensitivity comparison of pathogenic aquatic fungal hyphae to sodium chloride, hydrogen peroxide, acetic acid and povidone iodine. *Kasetsart J Nat Sci*. 2011;45:84-89.
23. Beigel JH, Tomashek KM, Dodd LE, et al. Remdesivir for the treatment of Covid-19-final report. *N Engl J Med*. 2020;383(19):1813-1826. doi:10.1056/NEJMoa2007764
24. Cascella M, Rajnik M, Aleem A, et al. Features, evaluation, and treatment of coronavirus (COVID-19). *StatPearls [Internet]*. StatPearls Publishing; 2022.
25. WHO Rapid Evidence Appraisal for COVID-19 Therapies (REACT) Working Group, Sterne JAC, Murthy S, et al. Association between administration of systemic corticosteroids and mortality among critically ill patients with COVID-19: a meta-analysis. *JAMA*. 2020;324:1330-1341. doi:10.1001/jama.2020.17023
26. RECOVERY Collaborative Group, Horby P, Lim WS, et al. Dexamethasone in hospitalized patients with COVID-19. *N Engl J Med*. 2021;384:693-704. doi:10.1056/NEJMoa2021436
27. Prakash H, Chakrabarti A. Global epidemiology of Mucormycosis. *J Fungi (Basel)*. 2019;5(1):26. doi:10.3390/jof5010026
28. Sugar AM. Mucormycosis. *Clin Infect Dis*. 1992;14(Suppl 1):S126-S129. doi:10.1093/clinids/14.supplement\_1.s126
29. Song G, Liang G, Liu W. Fungal co-infections associated with global COVID-19 pandemic: a clinical and diagnostic perspective from China. *Mycopathologia*. 2020;185(4):599-606. doi:10.1007/s11046-020-00462-9
30. Singh AK, Singh R, Joshi SR, Misra A. Mucormycosis in COVID-19: a systematic review of cases reported worldwide and in India. *Diabetes Metab Syndr*. 2021;15(4):102146. doi:10.1016/j.dsx.2021.05.019
31. Baghel SS, Keshri AK, Mishra P, et al. The spectrum of invasive fungal sinusitis in COVID-19 patients: experience from a tertiary care referral center in Northern India. *J Fungi (Basel)*. 2022;8(3):223. doi:10.3390/jof8030223
32. Ismaiel WF, Abdelazim MH, Eldsoky I, et al. The impact of COVID-19 outbreak on the incidence of acute invasive fungal rhinosinusitis. *Am J Otolaryngol*. 2021;42(6):103080. doi:10.1016/j.amjoto.2021.103080
33. Deutsch PG, Whittaker J, Prasad S. Invasive and non-invasive fungal rhinosinusitis-a review and update of the evidence. *Medicina (Kaunas)*. 2019;55(7):319. doi:10.3390/medicina55070319
34. Maartens G, Wood MJ. The clinical presentation and diagnosis of invasive fungal infections. *J Antimicrob Chemother*. 1991;28(Suppl A):13-22. doi:10.1093/jac/28.suppl\_a.13
35. Sharma S, Grover M, Bhargava S, Samdani S, Kataria T. Post coronavirus disease mucormycosis: a deadly addition to the pandemic spectrum. *J Laryngol Otol*. 2021;135(5):442-447. doi:10.1017/S0022215121000992
36. Benhadid-Brahmi Y, Hamane S, Soyer B, et al. COVID-19-associated mixed mold infection: a case report of aspergillosis and mucormycosis and a literature review. *J Mycol Med*. 2021;32(1):101231. doi:10.1016/j.mycmed.2021.101231
37. Ghasemian A, Asadollahzadeh M, Saraeian A, et al. Effect of acetic acid on growth and ethanol fermentation of filamentous fungi



- Rhizopus oryzae*, *Mucor indicus*, *Neurospora intermedia*, and *Aspergillus oryzae*. *Q J Exp Anim Biol*. 2019;7(3):119-130.
38. Uyar GE, Uyar B. Effects of ethanol and ultraviolet-c treatments on inactivation of *Rhizopus oryzae* spores which cause postharvest rot. *Food Sci Technol (Campinas)*. 2019;39(3):691-695. doi:10.1590/fst.04618
39. Korukluoglu M, Sahan Y, Yigit A. The fungicidal efficacy of various commercial disinfectants used in the food industry. *Ann Microbiol*. 2006;56(4):325-330.
40. Cornely OA, Arikan-Akdagli S, Dannaoui E, et al. ESCMID and ECMM joint clinical guidelines for the diagnosis and management of mucormycosis 2013. *Clin Microbiol Infect*. 2014;20(Suppl 3):5-26. doi:10.1111/1469-0691.12371
41. Romero M, Messina F, Marin E, et al. Antifungal resistance in clinical isolates of *Aspergillus* spp.: when local epidemiology breaks the norm. *J Fungi (Basel)*. 2019;5(2):41. doi:10.3390/jof5020041
42. Arikan S, Sancak B, Alp S, Hascelik G, McNicholas P. Comparative in vitro activities of posaconazole, voriconazole, itraconazole, and amphotericin B against *Aspergillus* and *Rhizopus*, and synergy testing for *Rhizopus*. *Med Mycol*. 2008;46(6):567-573. doi:10.1080/13693780801975576
43. Blum G, Perkhofer S, Haas H, et al. Potential basis for amphotericin B resistance in *aspergillus terreus*. *Antimicrob Agents Chemother*. 2008;52(4):1553-1555. doi:10.1128/AAC.01280-07
44. Purkait B, Kumar A, Nandi N, et al. Mechanism of amphotericin B resistance in clinical isolates of *Leishmania donovani*. *Antimicrob Agents Chemother*. 2012;56(2):1031-1041. doi:10.1128/AAC.00030-11

**How to cite this article:** Eldsouky SM, Shahat AK, AL-Tabbakh A-S, et al. Clinical and mycological investigations of post-COVID-19 acute invasive fungal sinusitis. *Laryngoscope Investigative Otolaryngology*. 2022;1-10. doi:10.1002/lio2.956